

Forefoot Ulcers: 5 Keys to Surgical Success

AHMED KAMAL, M.D.

The Department of Plastic Surgery, Assiut University Hospital, Faculty of Medicine, Assiut University, Assiut, Egypt

ABSTRACT

Background: The majority of plantar ulcers occur because of diabetic neuropathy, most frequently over the first metatarsal head. Plantar reconstruction is challenging because of the unique anatomical features of this region. The ideal surgical management for plantar wounds is reconstruction with local plantar tissue.

Patients: 75 patients with planter ulceration of the forefoot underwent surgery. Ages ranged from 25 years to 63 years, with a mean age of 49 years. Half the patients (37) had ulcers located medially, 26 in the central and 12 on the lateral aspect of the foot.

Methods: Local transposition flaps were used in all cases. Laterally-based flaps were used for the most common medial ulcers, medial-based flaps used for lateral ulcers, and sometimes both medial and lateral based flaps were used for central ulcers.

Results: 65 (86.7%) patients had primary healing of their wounds with good cosmetic outcome. 4 (5.3%) patients had mild flap compromise with delayed healing, 3 (4%) patients experienced a small dehiscence and 3 (4%) patients had ischemia of distal one cm of flap.

Conclusion: In this series of 75 patients, surgical excision and reconstruction of forefoot ulcers with local flaps has proven successful in over 85% of cases.

Key Words: Forefoot ulcer – Algorithm for forefoot ulcer – Planter ulcer – Forefoot reconstruction.

INTRODUCTION

A chronic foot ulcer is defined as an ulcer that fails to heal within 3 months using standard treatment [1,2]. The large majority of neuropathic plantar ulcers develop below the first metatarsal head where the greatest pressures are generated. This is not only the result of body weight causing pressure necrosis, but also from the shearing force produced by the rotation of the metatarsal heads during walking over a fixed planter skin. Where there is normal plantar sensation, early lesions result in pain and the patient shifts the pressure to another area of the foot [3-5]. With the worldwide epidemic of diabetes and obesity, plantar ulceration (with its major impairment of the quality of life) has become an important health problem [6-8]. Espe-

cially in diabetic patients, foot ulceration can result in long, expensive hospitalizations, and eventual amputation if not properly treated [9-13]. The ideal surgical management for plantar ulcers requires reconstruction with tough, long-lasting plantar tissue, i.e., local flaps. The glabrous skin of the sole is unique: Thick, tough, and resistant to pressure and shearing [14]. The reconstruction of planter foot ulcers is challenging, because while local sole tissue is ideal, it is neither elastic nor abundant. [15,16].

Aim of the work:

The primary goal in the treatment of forefoot planter ulcers is to obtain wound coverage by using local transposition flaps with a simple and effective algorithm.

PATIENTS AND METHODS

75 patients satisfying the inclusion criteria (below) underwent surgery in our plastic surgery department.

An informed consent was obtained from the participants.

Inclusion criteria:

- Forefoot ulcer persisting for ≥ 3 months.
- Adequate circulation to the foot: With palpable dorsalis pedis and/or posterior tibial pulse, or.
- Ankle-brachial indices (ABI) ≥ 0.8 .

Exclusion criteria:

- Impalpable pulses or ABI < 0.8 .
- Ulcers with life-threatening infection requiring amputation.
- Severe respiratory disease precluding general anesthesia.
- Potentially life-threatening primary disease such as hematopoietic system diseases, AIDS or HIV positive.
- Severe malnutrition as evidenced by albumin < 2.0 or having a history of bleeding disorder.

- Peripheral vascular disease.
- Highly exudative ulcer.
- Patient on oral or parenteral corticosteroids, immunosuppressive or cytotoxic agents.

Surgical technique -5 keys to Success:

Under anesthesia, patients were placed in a supine position and a tourniquet applied:

- 1- Wide excision of chronic forefoot planter ulcer, including the hyperkeratotic border, combined with removal of underlying prominent part of metatarsal head bone.
- 2- Place the upper incision of the flap at the junction between toes and forefoot.
- 3- Create a very thick plantar flap, the surgical plane just superficial to the tendon and periosteum over the metatarsals.
- 4- After incising transversely to the base of little toe (for lateral based flap), if additional tissue is needed, make a vertical incision 1cm dorsal to the junction between dorsal and planter aspect of foot. This places the skin graft in a non-weight bearing area.
- 5- For a central ulcer-start with medial or lateral flap, according to the largest available healthy area. If coverage is inadequate, use 2 flaps (both medial and lateral flaps).

Post-operative care:

Flaps are monitored with clinical assessment. The post-operative care regimen includes bed rest with leg elevation to reduce edema. Patients can usually be discharged from the hospital as soon as sutures are removed, or the skin graft has taken. Ten patients (13.3%) had delayed healing, requiring a varying period of additional hospital care. (See Complications, below).

Student *t*-test was used to compare the mean difference between the two groups.

Chi-square analysis was used to compare the difference in proportions.

A value of $p < 0.05$ was considered statistically significant.

RESULTS

Patients were followed for 6 to 18 months with average 9.1 months. Limb salvage was achieved in all patients. No additional revision surgery of the flap was needed once the wound healed. All patients were able to ambulate postoperatively once they were allowed to do so and after complete healing of wounds, usually after 4 weeks postoperatively.

The most common location of plantar ulcer was under the first metatarsal head, with 37 (49.3%) cases. About a third (26 or 34.7%) of patients had an ulcer in middle of the foot, and the least common site (12 or 16%) was under 5th metatarsal head. The mean size of the forefoot plantar flap was $9.5 \pm 6.8 \text{ cm}^2$ (range, 1.5-30 cm^2).

Diabetes mellitus was the most common etiology of plantar ulcers, recorded in 65 (86.7%) patients, trophic ulcers due to spinal cord affection in 8 (10.6%) cases, and leprotic ulcers in 2 (2.7%) patients. All patients had unilateral ulcer. 40 (53.3%) patients had their ulcer on the right foot and 35 (46.7%) patients on left side. 58 (77.3%) patients were males and 17 (22.7%) were female, (Table 1).

In this series, planter ulcers were reconstructed by medial, lateral or both transposition flaps with or without donor skin graft according to the site and size of the ulcer, after excision of ulcer including the hyperkeratotic border. 36 (48%) patients with ulcers below 1st metatarsal head and width of ulcer $\leq 4 \text{ cm}$, were reconstructed successfully with lateral transposition flaps. One (1.3%) patient who had a larger ulcer (4.5cm wide) was reconstructed with a lateral transposition flap and skin graft. 12 (16%) patients who had lateral ulcers (below 5th metatarsal head) and ulcer width $\leq 4 \text{ cm}$, were reconstructed by medial transposition flaps. 17 (22.7%) patients with middle ulcers (width $\leq 3 \text{ cm}$), were covered by one side transposition flap. 7 (9.3%) patients with larger middle ulcers (3-5cm) were reconstructed by both side transposition flap. Two (2.6%) patients with the largest middle ulcer (5 to 5.5cm), were reconstructed by one side transposition flap and other side transposition flaps with donor skin graft (Fig. 7). 65 (86.7%) patients had primary healing of their wounds (Table 1).

Complications:

- Four patients (5.3%) had delayed healing and discharge from the wound that healed after frequent dressings within 4 weeks postoperative, (Table 1).
- Three patients (4%) had a small dehiscence that healed within 6 weeks with local wound care and frequent dressing changes (Table 1).
- Three patients (4%) had ischemia of distal one cm of flap and recurrent ulceration that healed by secondary intention within 3 months with daily cleaning, use of topical antiseptic ointment, and general medical care (Table 1).

Table (1): Patients' summary.

NO	Age Y	Sex	Location of ulcer	Width x Length	Surface area cm ²	Technique	Etiology	Site	Complication
1	55	M	Middle	3x4cm	12	Med. Transp. Flap	DM	Lt.	No
2	58	M	Middle	2.5x3cm	7.5	Med. Transp. Flap	DM	Rt.	No
3	49	M	Medial	2.7x3cm	8.1	Lat. Transp. Flap	DM	Lt.	No
4	60	M	Medial	2x3cm	6	Lat. Transp. Flap	DM	Rt.	No
5	44	M	Middle	5x5.5cm	27.5	Bilateral transp. Flap	DM	Lt.	Superficial ischemia in distal part of lateral flap that healed after 2 months of dressing
6	50	M	Middle	1.5x1cm	1.5	Lat. Transp. Flap	DM	Rt.	No
7	51	M	Medial	1.5x2cm	3	Lat. Transp. Flap	DM	Lt.	No
8	53	M	Middle	3x3.5cm	10.5	Lat. Transp. Flap	DM	Rt.	No
9	48	M	Lateral	1.5x1.5cm	2.25	Med. Transp. Flap	DM	Rt.	No
10	48	M	Lateral	2x2.5cm	5	Med. Transp. Flap	DM	Lt.	No
11	46	M	Middle	2x1.5cm	3	Med. Transp. Flap	DM	Lt.	Small dehiscence and healed by dressing for 3 weeks
12	56	M	Lateral	2x2cm	4	Med. Transp. Flap	DM	Rt.	No
13	40	F	Middle	4x3.5cm	14	Bilat. Transp. Flap	DM	Lt.	No
14	55	F	Middle	3x3cm	9	Med. Transp. Flap	DM	Rt.	No
15	59	M	Middle	4x4cm	16	Bilat. Transp. Flap	DM	Lt.	No
16	60	M	Lateral	2x2.5cm	5	Med. Transp. Flap	DM	Rt.	No
17	50	M	Lateral	2x2cm	4	Med. Transp. Flap	DM	Lt.	No
18	44	M	Middle	3x3.5cm	10.5	Lat. Transp. Flap	DM	Rt.	No
19	48	M	Middle	2.5x2.5cm	6.25	Med. Transp. Flap	DM	Rt.	No
20	45	F	Medial	1.5x2cm	3	Lat. Transp. Flap	DM	Lt.	No
21	47	M	Medial	2x2cm	4	Lat. Transp. Flap	DM	Rt.	No
22	47	M	Lateral	2x2cm	4	Med. Transp. Flap	DM	Lt.	No
23	52	M	Middle	3x3.5cm	10.5	Med. Transp. Flap	DM	Rt.	No
24	49	F	Middle	5.2x5.8cm	30.1	Medial transp. Flap+ graft and Lat. Transp. Flap	DM	Lt.	Some dehiscence and healed by dressing for 6 weeks
25	55	M	Medial	2x2cm	4	Lat. Transp. Flap	DM	Rt.	No
26	39	M	Middle	2.5x3cm	7.5	Lat. Transp. Flap	DM	Lt.	No
27	43	M	Middle	3x4cm	12	Lat. Transp. Flap	DM	Rt.	No
28	51	M	Middle	5.3x5.5cm	29.15	Med. Transp. Flap and Lat. Transp. Flap + graft	DM	Lt.	No
29	49	M	Lateral	4x3.5cm	14	Med. Transp. Flap	DM	Rt.	No
30	61	M	Middle	3.5x4cm	14	Bilat. Transp. Flap	DM	Rt.	No
31	47	M	Medial	3x3.5cm	10.5	Lat. Transp. Flap	DM	Rt.	No
32	47	M	Middle	3x3.5cm	10.5	Med. Transp. Flap	DM	Lt.	No
33	29	M	Middle	1x1.5cm	1.5	Lat. Transp. Flap	DM	Lt.	No
34	25	M	Medial	1.5x1.5cm	2.25	Lat. Transp. Flap	DM	Lt.	No
35	38	M	Medial	1x1.5cm	1.5	Lat. Transp. Flap	DM	Rt.	No
36	54	M	Middle	3x3.5cm	10.5	Lat. Transp. Flap	DM	Lt.	No
37	46	M	Medial	2.5x3cm	7.5	Lat. Transp. Flap	DM	Lt.	No
38	43	F	Lateral	3x3cm	9	Med. Transp. Flap	DM	Rt.	No
39	54	M	Medial	3x3cm	9	Lat. Transp. Flap	DM	Rt.	Discharge healed after 3 weeks of dressing

Table (1): Cont.

NO	Age Y	Sex	Location of ulcer	Width x Length	Surface area cm ²	Technique	Etiology	Site	Complication
40	59	F	Middle	2.5x3cm	7.5	Lat. Transp. Flap	DM	Rt.	No
41	56	M	Medial	1.5x2cm	3	Lat. Transp. Flap	DM	Lt	No
42	63	F	Medial	2x2.5cm	5	Lat. Transp. Flap	DM	Rt	No
43	48	M	Middle	1.5x1.5cm	2.25	Med. Transp. Flap	DM	Lt.	No
44	50	F	Medial	3x3cm	9	Lat. Transp. Flap	DM	Lt.	No
45	59	F	Lateral	1.5x2cm	3	Med. Transp. Flap	DM	Lt.	No
46	54	M	Medial	2x3cm	6	Lat. Transp. Flap	DM	Lt.	No
47	39	M	Medial	2x2.5	5	Lat. Transp. Flap	Trophic	Rt.	No
48	40	M	Medial	3.5x4	14	Lat. Transp. Flap	Trophic	Lt	No
49	46	F	Medial	2.5x3cm	7.5	Lat. Transp. Flap	Trophic	Rt.	No
50	50	M	Medial	4x4.5cm	18	Lat. Transp. Flap	Trophic	Rt.	Some dehiscence and healed after 5 weeks dressing
51	30	M	Medial	2x2cm	4	Lat. Transp. Flap	Trophic	Lt	No
52	47	F	Medial	1.5x2cm	3	Lat. Transp. Flap	Trophic	Rt	No
53	41	M	Middle	3.5x4cm	14	Bilat. Transp. Flap	Trophic	Rt.	No
54	34	M	Medial	2x3cm	6	Lat. Transp. Flap	Trophic	Rt.	No
55	56	M	Medial	4x4.5cm	18	Lat. Transp. Flap	DM	Rt.	Discharge healed after 4 weeks of dressing
56	56	M	Medial	2x3cm	6	Lat. Transp. Flap	Leprotic	Lt.	No
57	49	M	Medial	4x5cm	20	Lat. Transp. Flap	Leprotic	Rt	Discharge healed after one month
58	58	M	Medial	3.5x4cm	14	Lat. Transp. Flap	DM	Rt	No
59	56	M	Middle	4.5x5	22.5	Bilat. Transp. Flap	DM	Lt	No
60	55	F	Lateral	3x5cm	15	Med. Transp. Flap	DM	Rt	No
61	59	M	Medial	5x5cm	25	Lat. Transp. Flap + Graft	DM	Lt	Ischemia in distal one cm, healed by dressing for three months
62	48	F	Middle	4x5.5cm	22.5	Bilat. Transp. Flap	DM		Discharge for 3 weeks
63	49	F	Medial	2x3cm	6	Lat. Transp. Flap	DM	Rt	No
64	57	M	Medial	1.5x2cm	3	Lat. Transp. Flap	DM	Lt	No
65	60	M	Medial	1.5x1.5cm	2.25	Lat. Transp. Flap	DM	Rt	No
66	38	M	Lateral	3.5x4cm	14	Med. Transp. Flap	DM	Rt	Ischemia in distal one cm healed after 2 months of dressing
67	37	M	Middle	3x2.5	7.5	Med. Transp. Flap	DM	Rt	No
68	47	F	Medial	2x3.5cm	7	Lat. Transp. Flap	DM	Lt	No
69	56	M	Medial	2.5x2cm	5	Lat. Transp. Flap	DM	Rt	No
70	51	M	Medial	3.5x4cm	14	Lat. Transp. Flap	DM	Lt	No
71	48	F	Medial	3x3cm	9	Lat. Transp. Flap	DM	Rt	No
72	47	M	Lateral	3x3.5cm	10.5	Med. Transp. Flap	DM	Rt	No
73	50	M	Medial	1.5x2cm	3	Lat. Transp. Flap	DM	Lt	No
74	49	M	Medial	4x3.5cm	14	Lat. Transp. Flap	DM	Rt	No
75	52	F	Medial	4x5cm	20	Lat. Transp. Flap	DM	Lt	No

Dm : Diabetes Mellitus.
Rt. : Right.

Lt. : Left.
Med. : Medial.

Lat. : Lateral.
Bilat. : Bilateral.

Transp. : Transposition.
M : Male.

F : Female.
Y : Year.

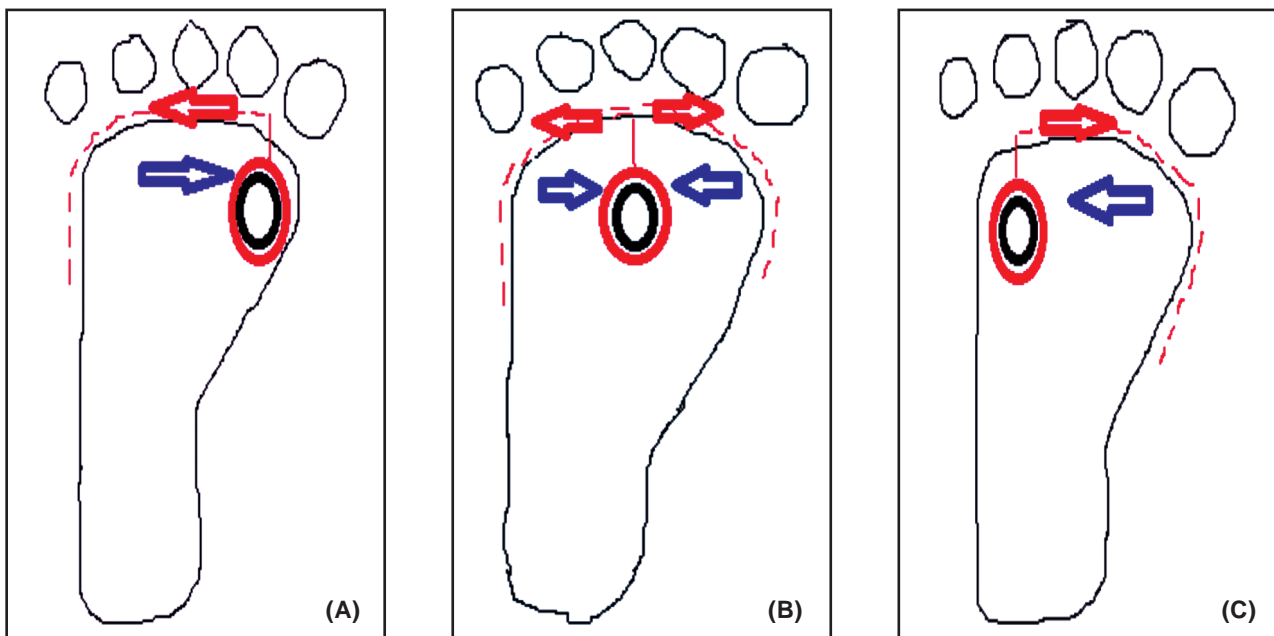


Fig. (1): Diagram shows the surgical technique of forefoot ulcer coverage where the dotted red line represent the site of incision, red arrow represents the direction of incision and the blue arrow represents the direction of flap movement, the black circle represents the ulcer and the red circle represents the ulcer after excision including the hyperkeratotic border. (A) For medial ulcer, (B) Middle, and (C) Represents lateral ulcer.

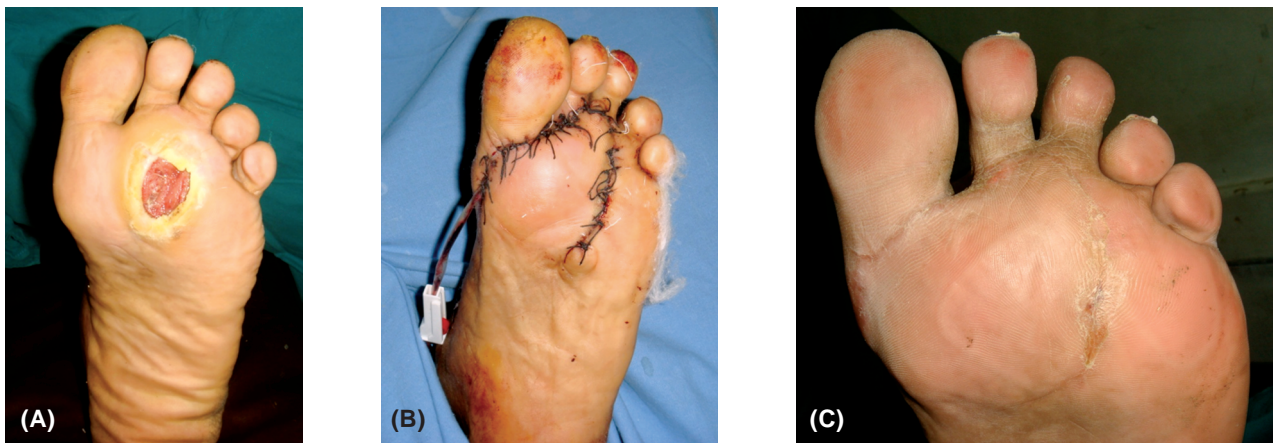


Fig. (2): A 55-year-old diabetic male patient with 3x4cm ulcer in middle aspect of left forefoot. (B) Intraoperative view showing medial transposition flap covering the defect. (C) Six months postoperatively.

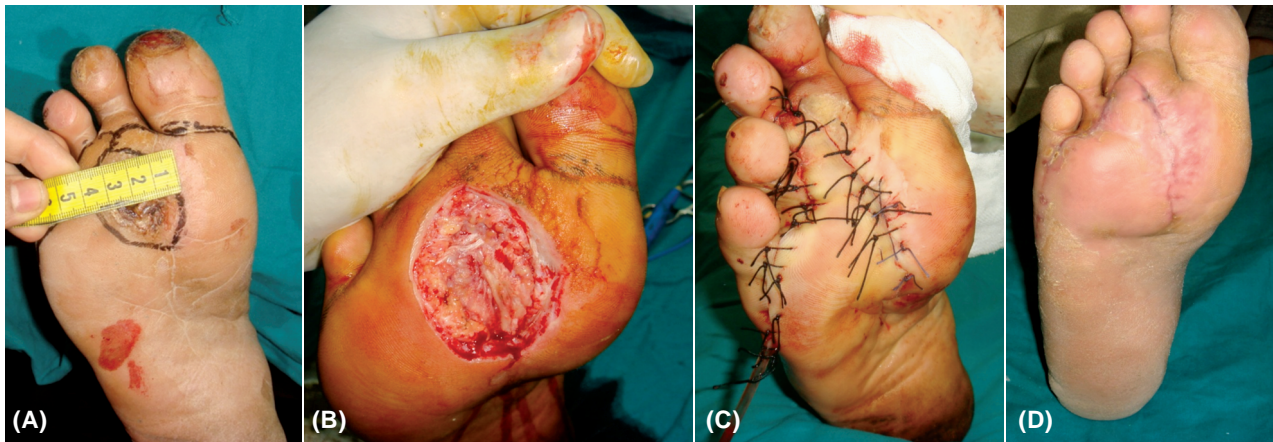


Fig. (3): (A) 53-year-old male patient with 3x3.5cm ulcer in middle aspect of right forefoot. (B) Intraoperative view after excision of ulcer including hyperkeratotic border. (C) Intraoperative view showing lateral transposition flap covering the ulcer. (D) Two months postoperatively.

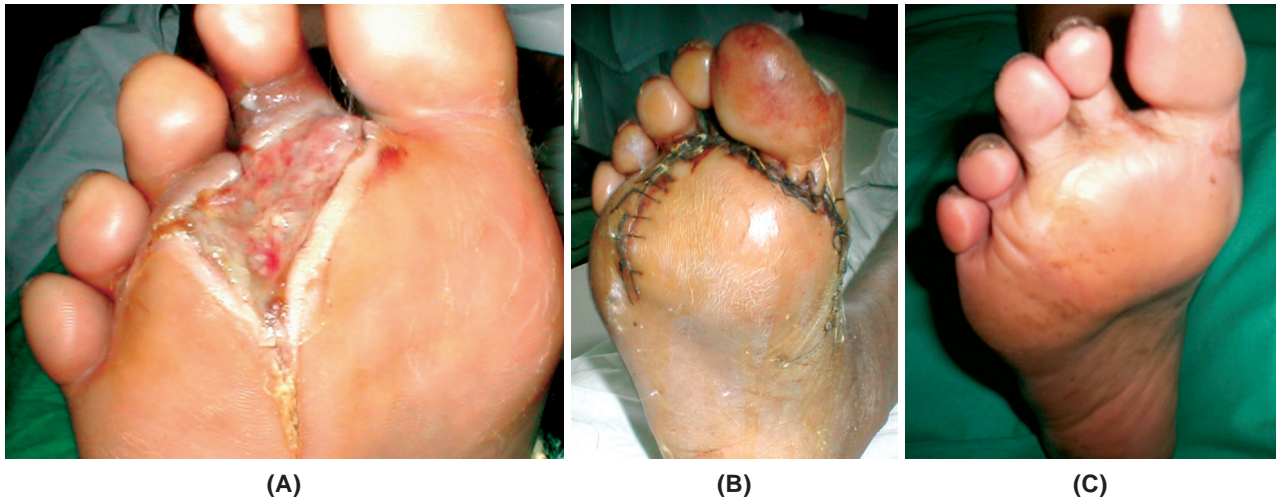


Fig. (4): (A) 48-year-old male patient with 2.5x2.5cm ulcer in middle aspect of right forefoot. (B) Intraoperative view showing medial transposition flap covering the defect. (C) Five months postoperatively.

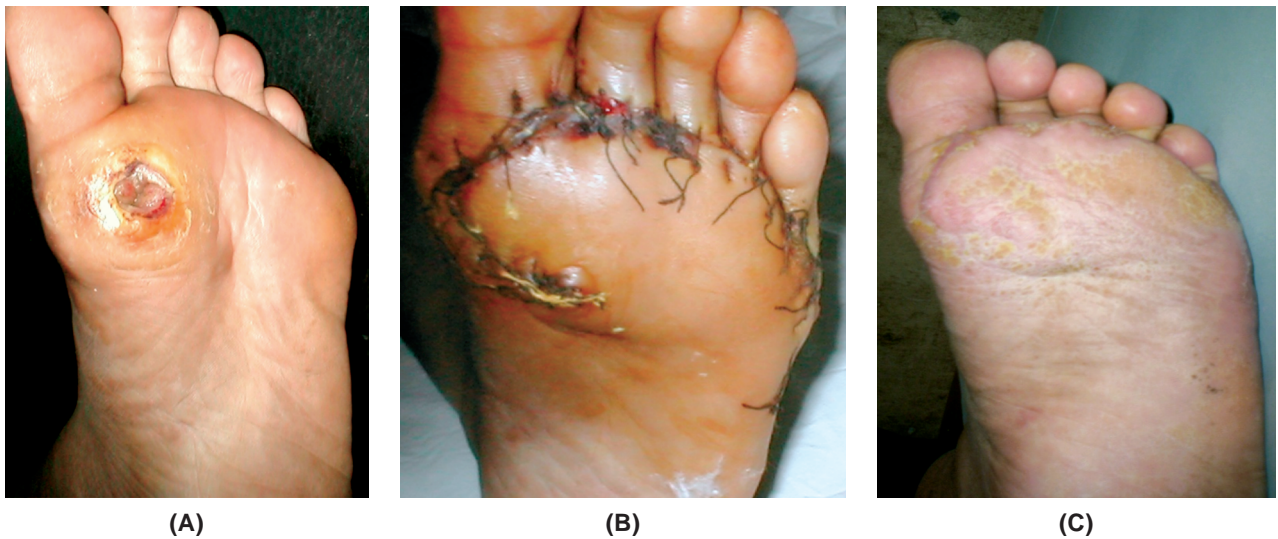


Fig. (5): (A) 49-year-old male patient with 2.7x3cm ulcer in medial aspect of left forefoot. (B) Intraoperative view showing lateral transposition flap covering the defect. (C) Three months postoperatively.

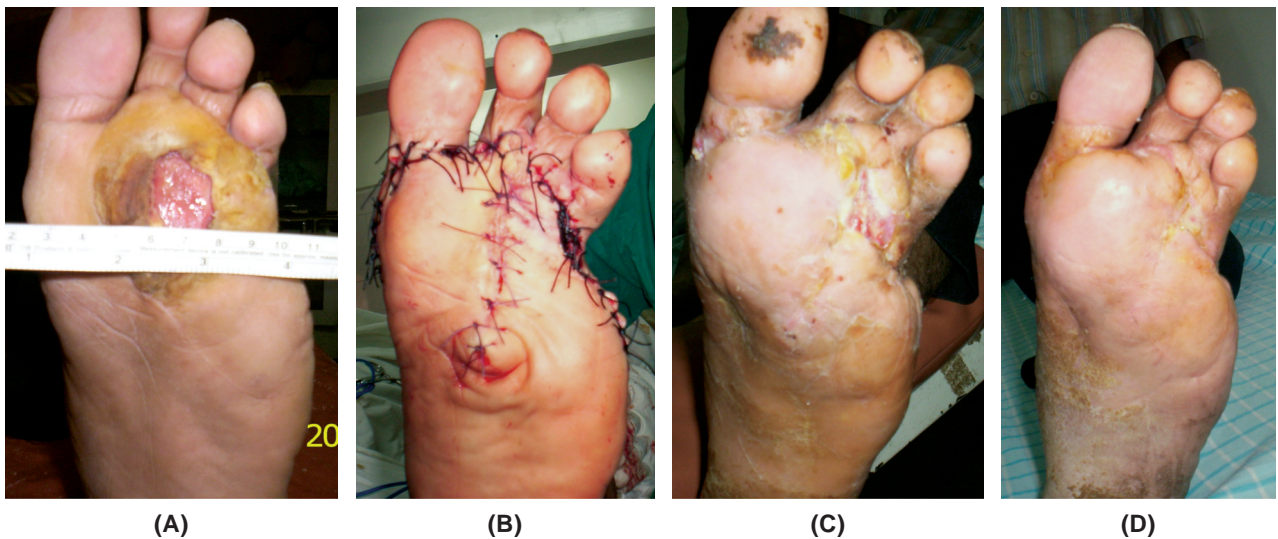
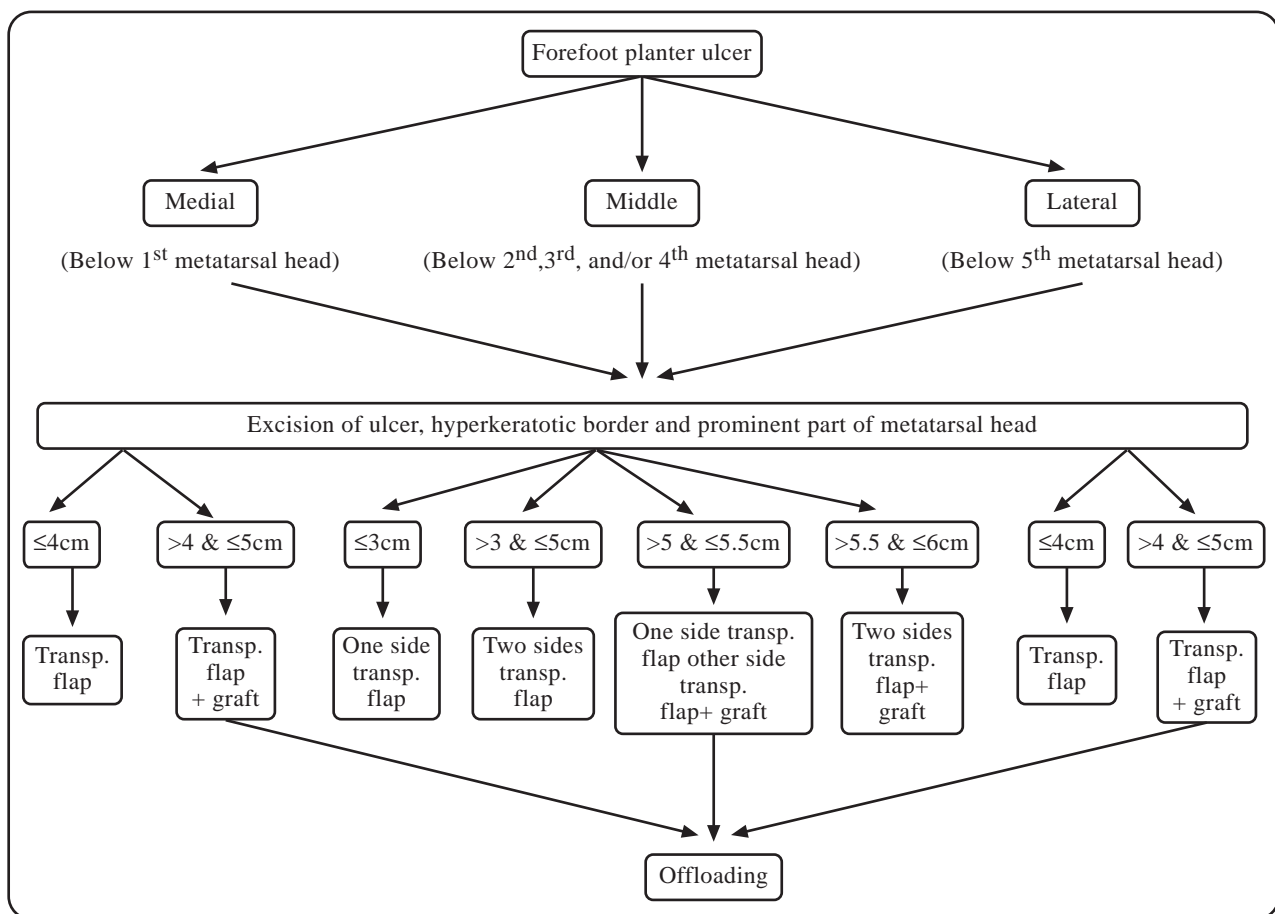


Fig. (6): (A) 44-year-old male diabetic patient who had 5x5.5 cm ulcer in middle aspect of left forefoot. (B) Intraoperative view showing bilateral transposition flap covering the defect. (C) Ischemia in distal part of lateral flap 48 days postoperatively. (D) Two months postoperatively.



Transp: Transposition

Fig. (7): An algorithm for getting the most out and selecting the best choice of the local flap for reconstruction of forefoot ulcer.

There was a statistically significant difference between etiology, size of ulcers, and complication rate. More complications occurred with diabetic ulcers than trophic or leprotic ulcers (p -value <0.05). There was also a significant difference between size of ulcers and the complications: Larger ulcers (mean width of 4.1cm) had more complications, fewer complications in smaller (mean of 2.5cm) ulcers p -value <0.001 .

There was no statistically significant difference between sex, age, site and location of forefoot ulcers and the complications.

DISCUSSION

Surgical reconstruction of planter ulcers is difficult, because the thick glabrous skin of the plantar surface of foot is relatively inelastic and not abundant. Local flaps are mandatory, in order to provide durable coverage and mechanical resistance to shear stress and pressure [14,15,17]. In the neuropathic foot, there is a change in foot mechanics. This change in mechanics increases the prom-

inence of the metatarsal heads. This leads to excessive load bearing, mainly on the metatarsal heads, which then become more prone to irritation by shoes. The most common site of neuropathic ulceration occurs under the first metatarsal head where the forces are greatest [18-21]. Less commonly, ulcers appear under the second and fifth metatarsophalangeal joints [4,5]. Our study confirmed this, as about half of our ulcers occurred under the first metatarsal head. An ideally healed wound is characterized by restoration of function, appearance and anatomic continuity [22]. In this study we achieved this goal by reconstructing the planter ulcer using local tissue flaps of thick, durable plantar skin. The incisions, and when necessary the skin grafts, were placed in non-weight bearing areas. Split skin-grafting for weight bearing planter defects is a poor option because of defective durability of the skin cover. Breakdown of split skin-grafted areas is common with daily ambulation and footwear pressure [23,24]. All the foot ulcers in this study were in the forefoot and this is a weight bearing area that needs a durable coverage

to support the body weight. We achieved coverage of the weight bearing plantar ulcers using local flaps of thick sole tissue. Protecting the abnormal pressure points that predispose the diabetic foot to ulceration is essential for the prevention of ulcer formation and this occurs by wearing an offloading shoe [25]. In this study, excision of the prominent part of metatarsal head and offloading are important to manage and prevent recurrence of forefoot planter ulcers.

Conclusion:

In our study of 75 patients with plantar ulcers, we identified 5 keys to surgical success:

- 1- Always excise the prominent part of metatarsal head.
- 2- Place the upper incision of the flap at the depressed, junctional area between toes and forefoot.
- 3- Create a very thick flap of plantar tissue.
- 4- Place the lateral or medial incision of the flap 1cm dorsal to the junction between dorsal and plantar aspects.
- 5- Only use skin grafts for flap donor sight, and always place in non weight-bearing area.

In addition, use an offloading shoe and patient education to prevent recurrence after surgery.

Disclosure: None.

REFERENCES

- 1- Nomikos I.N., Malizos C. and Vamvakopoulos N.: Protective and damaging aspects of healing: A review. *Wounds*, 18: 177-85, 2006.
- 2- Yager D. and Nwomeh B.: The proteolytic environment of chronic wounds. *Wound Repair Regen*, 7: 433-41, 1999.
- 3- Prompers L., Huijberts M., Apelqvist J., Jude E., Piaggese A., Bakker K., et al.: High prevalence of ischaemia, infection and serious comorbidity in patients with diabetic foot disease in europe. Baseline results from the Eurodiale study. *Diabetologia*, 50: 18-25, 2007.
- 4- Penn I.: Diabetes mellitus and the surgeon. *Curr. Probl. Surg.*, 24: 564, 1987.
- 5- O'Neal L.W.: Surgical pathology of the foot and clinico-pathologic correlations. In M.E. Levin and L.W. O'Neal (Eds.), *The Diabetic Foot*, 3rd Ed. St Louis: Mosby, 1983.
- 6- Ragnarson-Tennvall G. and Apelqvist J.: Health-economic consequences of diabetic foot lesions. *Clin. Infect. Dis.*, 39: 132-9, 2004.
- 7- Margolis D.J., Allen-Taylor L., Hoffstad O. and Berlin J.A.: Diabetic neuropathic foot ulcers and amputation. *Wound Repair Regen*, 13: 230-6, 2005.
- 8- Leung P.C.: Diabetic foot ulcers -a comprehensive review: *Surgeon*, 5; 4: 219-31, 2007.
- 9- American Diabetes Association, Inc. Consensus Development Conference on Diabetic Foot Wound Care, 7-8 April, Boston, MA. *Diabetes Care*, 22: 1354-1 360, 1999.
- 10- Pecoraro R.E., Reiber G.E. and Burgess E.M.: Pathways to diabetic limb amputation: Basis for prevention. *Diabetes Care*, 13: 513-521, 1990.
- 11- Cavanagh P.R., Ulbrecht J.S. and Caputo G.M.: The non-healing diabetic foot wound: Fact or fiction? *Ostomy Wound Management*, 44: 6S-12S, 1998.
- 12- Margolis D.J., Kantor J. and Berlin J.A.: Healing of diabetic neuropathic foot ulcers receiving standard treatment. A meta-analysis. *Diabetes Care*, 22: 692-695, 1999.
- 13- Sinacore D.R.: Healing times of diabetic ulcers in the presence of fixed deformities of the foot using total contact casting. *Foot and Ankle International*, 19: 613-618, 1998.
- 14- Brenda K., Cohen D.P., David D., Zabel E., Douglas Newton and Alan R.: Catanzariti. Soft-tissue reconstruction for recalcitrant diabetic foot wounds: *The Journal of Foot & Ankle Surgery*, 38 (6): 388-393, 1999.
- 15- Francisco Giraldo, Fabiola De Haro and Arminda Ferrer: Opposed transverse extended V-Y plantar flaps for reconstruction of neuropathic metatarsal head ulcers: *Plast. Reconstr. Surg.*, 108 (4): 1019-1024, 2001.
- 16- Steed D.L., Attinger C., Colaizzi T., Crosland M., Franz M., Harkless L., et al.: Guidelines for the treatment of diabetic ulcers. *Wound Repair Regen*, 14: 680-92, 2006.
- 17- Potparic Z. and Rajacic N.: Long-term results of weight-bearing foot reconstruction with non-innervated and reinnervated free flaps. *Br. J. Plast. Surg.*, 50 (3): 176-181, 1997.
- 18- Sicco A., Bus A.B., Robert W.M., Van Deursen C., Rajani V., Kanade C., Marieke Wissink A., Erik A., Manning A., Jeff G., Van Baal A. and Keith G.: Harding. Plantar pressure relief in the diabetic foot using forefoot offloading shoes. *Gait and Posture*, 29: 618-622, 2009.
- 19- Gibbons G.W.: The diabetic foot: Amputations and drainage of infection. *J. Vasc. Surg.*, 5: 791-3, 1987.
- 20- Lipsky B.A., Pecararo R.E. and Wheat L.J.: The diabetic foot, soft tissue and bone infection. *Infect. Dis. Clin. North. Am.*, 4: 409-32, 1990.
- 21- Caputo G.M., Cavanagh P.R., Vlbrecht J.S., et al.: Assessment and management of foot disease in patients with diabetes *NEJM*, 331: 854-60, 1994.
- 22- Lazarus G.S., Cooper D.M., Knighton D.R., et al.: Definitions and guidelines for assessment of wounds and evaluation of healing. *Arch. Dermatol.*, 130: 489-493, 1994.
- 23- Wieman T.J.: Principles of management: The diabetic foot. *Am. J. Surg.*, 190: 295-9, 2005.
- 24- Patel V.G. and Wieman T.J.: Effects of metatarsal head resection for diabetic foot ulcers on the dynamic plantar pressure distribution. *Am. J. Surg.*, 167: 297-301, 1994.
- 25- Ramsey S.D., Newton K., Blough D., McCulloch D.K., Sandhu N., Reiber G.E. and Wagner E.H.: Incidence, outcomes and costs of foot ulcers in patients with diabetes. *Diabetes Care*, 22: 382-7, 1999.